Southern Health and Social Care Trust

Smoke and Mirrors: A Case of EVALI During the COVID-19 Pandemic

HuaJian Liu[1], Raymond McKee[2], Rory Convery[3]

1. Department of Medicine, Mater Infirmorum Hospital, 45-51 Crumlin Road, Belfast, UK; 2. Intensive Care Unit, Craigavon Area Hospital, 68 Lurgan Road, Portadown, UK; 3. Department of Medicine, Craigavon Area Hospital, 68 Lurgan Road, Portadown, UK

ABSTRACT

The use of electronic cigarettes has surged in recent years, with e-cigarette or vaping product use-associated lung injury (EVALI) increasingly recognised. EVALI is a diagnosis of exclusion, as clinical and radiological features overlap significantly with other respiratory conditions.

We present a case of EVALI in an immunocompetent 39-year-old male with a recent history of vaping. He presented with pleuritic pain, with CT showing changes suggestive of COVID-19 pneumonia. With negative microbiological evidence of COVID-19, he was managed as a "clinical COVID" case, but continued to deteriorate, and required admission to the intensive care unit, where he was trialed on high dose corticosteroids without improvement. Care was withdrawn and subsequent post-mortem revealed organising pneumonia, but laboratory testing failed to yield any infective or inflammatory aetiology. A diagnosis of EVALI was made following this.

EVALI can be life-threatening but can be steroid-responsive, although evidence is limited to case studies. Diagnosis is crucial but challenging due to non-specific findings, especially during the pandemic as a "mimic" of COVID pneumonia. We suggest that detailed vaping history and prompt multidisciplinary discussions in challenging cases can be of benefit to an earlier diagnosis.

Investigations

EVALI Fact Sheet

INITIAL CASE PRESENTATION

A 39-year-old male presented to the emergency department in a district general hospital in Northern Ireland in December 2020 with a 1-week history of shortness of breath, left sided pleuritic pain and haemoptysis on the background of recently vaping electronic cigarettes.

His past medical history included:

- Alcohol misuse
- E-cigarette vaping including tetrahydrocannabinol (THC) products, recreational cannabis use
- Asthma
- Depression

Pre-admission medications included citalopram, venlafaxine, and pregabalin.

His initial observations were as follows: heart rate 140 beats per minute, blood pressure 79/54 mmHg, temperature 36.0^{O}C, respiratory rate 30 breaths per minute, and oxygen saturation 90% on room air, which improved to 98% on 15 litres per minute oxygen. On examination, bilateral inspiratory crackles were heard throughout both lung fields.

Initial chest x-ray showed bibasal opacification suggestive of atypical pneumonia (Figure 1a), an arterial blood gas on room air revealed low partial arterial pressure of oxygen (pO_2) at 9 kPa. Blood tests showed an elevated White Cell Count at 17.0x10^9/L, with lymphopenia at 0.49x10^9/L, and a mildly elevated C-reactive protein at 14.05 mg/L.

TIMELINE OF EVENTS

Initial DDx

- Aspiration pneumonia – Amoxicillin + Metronidazole
- Atypical pneumonia (incl. COVID-19) – Dexamethasone + Remdesivir
- Pulmonary Embolism – therapeutic enoxaparin

Further Ix

- CT – no pulmonary embolism, bilateral ground glass changes suggestive of atypical pneumonia including COVID-19 (Figure 1B)
- COVID PCR negative but managed as "clinical COVID" – transferred to COVID ward
- Atypical pneumonia screen all negative (QR code "investigations")

Revised DDx

- Escalating O2 requirements – commenced on CPAP (15 l/min O_2, 10 cmH_2O)
- Revised differential diagnoses:
  - E-cigarette or vaping induced lung injury (EVALI)
  - Idiopathic interstitial pneumonia (IIP)

ICU

- Transferred to ICU after further deterioration on maximum CPAP settings
- RSI Intubation + mechanical ventilation – high oxygen and ventilation requirements
- Bronchoscopy and washings – no infective aetiology identified
- Trial of methylprednisolone 500mg IV for 3 days without improvement
- Withdrawal of care 9 days after ICU admission

Diagnosis

- Post-mortem – organising pneumonia
- Diagnosis of EVALI made with following CDC criteria:[2]
  - Use of an e-cigarette in the previous 90 days
  - Lung opacities on chest radiograph or CT
  - Exclusion of an infective aetiology
  - Absence of a likely alternative diagnosis (e.g., rheumatologic)

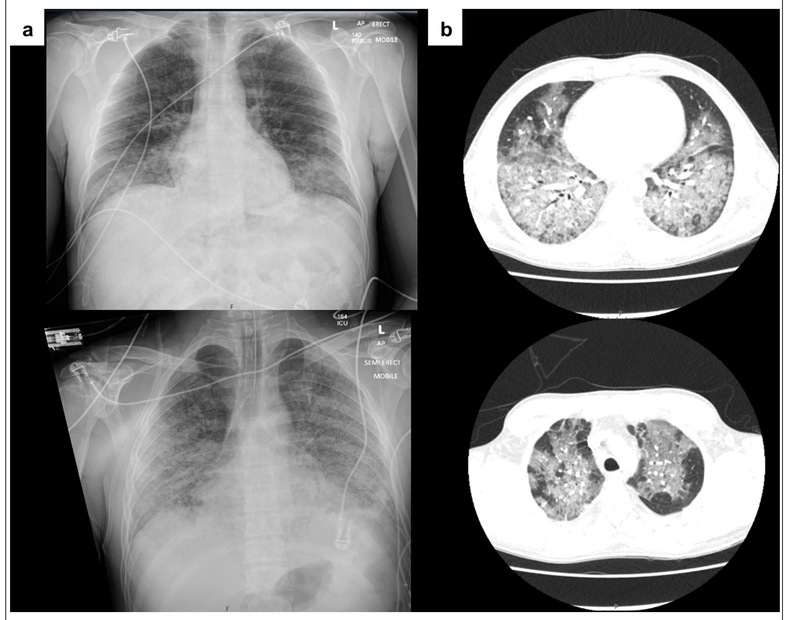

Figure 1a. Presenting chest x-ray in emergency department showing bilateral patchy consolidations (above) and post-intubation in ICU showing evolution of changes in both lung fields (below). 1b. CT chest showing bilateral ground glass opacification suggestive of atypical pneumonia.

DISCUSSION

2807 EVALI cases have been reported across the United States as of 2020, and with growing recognition of vaping-related complications, EVALI will become more widely reported globally in the coming years.[2]

Difficulties in recognition persist as EVALI remain a diagnosis of exclusion as it presents similar to common respiratory conditions.[3] During the COVID-19 pandemic, without specific features to suggest an alternative diagnosis, such a presentation can easily be attributed to another case of COVID-19, even without a positive PCR test.

Diagnosis of EVALI focuses on excluding other potential causes and obtaining a detailed vaping history.[3] CT typically shows bilateral ground glass opacification with basal predominance, and histopathological features most commonly show an organising pneumonia, both were seen in this case of EVALI.[4]

Data from case reports and product testing show (THC) and vitamin E acetate-containing e-cigarette products, are strongly linked to most EVALI cases. Vitamin E acetate has also been found from bronchial washing samples (QR code EVALI Fact Sheet).[1, 2]

Currently, the optimal treatment for EVALI is not known, and current practice of using systemic glucocorticoids are based on observational case studies only.[5]

EVALI can be life-threatening, with a quarter of hospitalised patients requiring intubation and mechanical ventilation, with a mortality rate of 2.4%. Poor prognostic factors include those aged 35 or older, a history of asthma, and those with a mental health condition, all of which were present in this case.[1]

KEY LEARNING POINTS

- In patients currently vaping presenting with acute respiratory symptoms, a detailed vaping history should part of the assessment.[1]
- A high index of suspicion for EVALI is needed in those vaping THC/vitamin E acetate containing products.[1, 2]
- Providing vaping history when requesting investigations in the appropriate clinical context can lead to EVALI being suggested as an early differential from imaging.[4]
- Obtaining laboratory investigations early can aid identification of other causes of atypical pneumonia, or rule these out in diagnosing EVALI.[5]

REFERENCES

1. Schier JG, Meiman JG, Layden J et al. Severe Pulmonary Disease Associated with Electronic-Cigarette–Product Use — Interim Guidance. Morbidity and Mortality Weekly Report 2019;68(36):787–90.
2. Centre for Disease Control. Outbreak of Lung Injury Associated with the Use of E-Cigarette, or Vaping, Products. 2020. https://www.cdc.gov/tobacco/basic_information/e-cigarettes/severe-lung-disease.html#latest-information [Accessed 12 July 2021].
3. Layden J, Ghinai I, Pray I et al. Pulmonary Illness Related to E-Cigarette Use in Illinois and Wisconsin - Final Report. New England Journal of Medicine 2020;382(10):903-16.
4. Kligerman S, Raptis C, Larsen B et al. Radiologic, Pathologic, Clinical, and Physiologic Findings of Electronic Cigarette or Vaping Product Use–associated Lung Injury (EVALI): Evolving Knowledge and Remaining Questions. Radiology 2020;294(3):491-505.
5. Doukas SG, Kavali L, Menon RS et al. E-cigarette or vaping induced lung injury: A case series and literature review. Toxicology Reports 2020;7(2020):1381-6.

CORRESPONDENCE

Dr Rory Convery, Craigavon Area Hospital, 68 Lurgan Road, Portadown BT63 5QQ United Kingdom
E-mail: rory.convery@southerntrust.hscni.net